Progrès en urologie (2019) **29**, 263—269

Disponible en ligne sur
ScienceDirect
www.sciencedirect.com

Elsevier Masson France
EM|consulte
www.em-consulte.com

ORIGINAL ARTICLE

Study of the intra-prostatic arterial anatomy and implications for arterial embolization of benign prostatic hyperplasia

suppl. Informations

Article of the month

Étude de la vascularisation intraprostatique appliquée à l'embolisation des artères prostatiques comme traitement de l'hyperplasie bénigne de prostate

J. Anract[a,*], G. Amouyal[b], M. Peyromaure[a], M. Zerbib[a], M. Sapoval[b], N. Barry Delongchamps[a]

[a] *Service d'urologie, hôpital Cochin, 163, boulevard de Port-Royal, 75014 Paris, France*
[b] *Service de radiologie interventionnelle, hôpital européen Georges-Pompidou, 20, rue Leblanc, 75015 Paris, France*

Received 7 December 2018; accepted 14 February 2019
Available online 1 April 2019

KEYWORDS
Prostate;
Hyperplasia;
Embolization;
Adenoma;
Arterial anatomy

Summary
Introduction. — Prostatic arterial embolization (PAE) is an experimental therapy for benign prostatic hyperplasia. Its feasibility is based on the knowledge of the pelvic arterial anatomy, and more specifically the prostate. The aim of this study was to describe the prostatic arterial supply: origins, distribution and variability.
Material and methods. — We reviewed retrospectively, with two radiologists, 40 arteriographies of patients who underwent PAE in our center. With these observations of 80 hemipelvics, we described the number of prostatic arteries, their origins, their distributions and eventually their anastomoses with other pelvic arteries.
Results. — There was one prostatic artery in 70% of the cases. It came from a common trunk for the prostate and the bladder in 55% of the cases, from the obturator artery in 17.5% of the cases, from the pudendal artery in 25% of the cases, from the intern iliac artery in 1% of the cases, and from the superior gluteal artery in 1% of the cases. The prostatic artery splitted in two branches (medial and lateral), with no anastomoses in 37% of the cases. Anastomoses with penile and rectal arteries were observed in 29% of the cases.

* Corresponding author.
E-mail address: juanract@me.com (J. Anract).

https://doi.org/10.1016/j.purol.2019.02.007

Conclusions. — For our 40 patients, we observed many variations of arterial prostatic anatomy. We proposed a classification in order to increase security and efficacy of PAE, and it should be validated with more patients.
Level of evidence. — 2.

MOTS CLÉS
Prostate ;
Hyperplasie ;
Embolisation ;
Adénome ;
Vascularisation

Résumé
Introduction. — L'embolisation des artères prostatiques (EAP) est un traitement expérimental de l'hyperplasie bénigne de la prostate. Sa faisabilité repose sur une connaissance précise de la vascularisation prostatique. L'objectif principal de ce travail était donc de décrire la vascularisation artérielle intra prostatique, de préciser ses origines, sa distribution et sa variabilité.
Matériel et méthodes. — Nous avons sélectionné rétrospectivement les artériographies pelviennes de 40 patients traités par EAP dans notre centre hospitalo-universitaire. Celles-ci ont été relues par deux radiologues. Pour chacune des 80 hémi-vascularisations prostatiques étudiées, nous avons décrit le nombre d'artères prostatiques, leur origine, leur mode de division et leurs anastomoses éventuelles avec d'autres artères du petit bassin.
Résultats. — L'artère prostatique était unique dans 70 % des cas. Son origine était observée au niveau du tronc antérieur de l'iliaque interne dans 55 % des cas, de l'obturatrice dans 17,5 % des cas, de l'artère pudendale interne dans 25 % des cas, de l'artère iliaque interne dans 1 % des cas, et de la glutéale supérieure dans 1 % des cas. L'artère prostatique se divisait en une branche médiale et une branche latérale, sans anastomose dans 37 % des cas. Des anastomoses avec des artères du pénis et du rectum ont été observées dans 29 % des cas.
Conclusions. — Chez les 40 patients étudiés, la distribution des artères prostatiques était hautement variable. Notre classification a pour ambition d'augmenter la sécurité et la faisabilité de l'EAP, et doit être validée sur un nombre plus important de patients.
Niveau de preuve.— 2.

Introduction

Prostatic arterial embolization (PAE) is currently under evaluation for the treatment of benign prostatic hyperplasia (BPH). The first feasibility study has been published by Carnevale et al. in 2010 [1]. Since then, two ranbdomised controlled trials suggested that the functionnal improvement after PAE was not inferior to trans urethral resection of the prostate (TURP) [2,3]. However, this procedure is technically difficult and a better knowledge of prostatic arterial vascularization is required for its development.

Autopsy studies showed a large variability of origins of the prostatic artery [4]. Other studies showed several pedicles, and anastomotic plexus with other pelvic arteries [5]. Recently, Amouyal et al. analysed for the first time intra-prostatic arterial vascularization and described three distribution modes of the prostatic artery [6].

The aim of our work was to describe the number of prostatic arteries, their origins, their distribution mode and anastomotic bounds. Our observations were made using retrospective arteriographic analysis of patients treated by PAE.

The second objective was to propose a validation, based on our results, of the classification proposed by Amouyal et al. [6].

Patients and methods

Population studied

Between December 2013 and July 2014, 40 male patients were treated by PAE for BPH in our center. Inclusion criteria were: male patients > 50 years old, low urinary tract symptoms (LUTS) due to BPH, prostate volume > 40 mL. Exclusion criteria were: bladder diverticula or bladder stone, renal failure, or suspision of prostate cancer.

PAE

PAE protocol was standardized. The right femoral artery was catheterized. Arterial prostatic cartography was performed using cone-Beam CT-scan, after catheterisation of the intern iliac artery. Embolization procedure started with selective catheterism of the left prostatic artery. In case of extra-prostatic anastomotic bound, targeted zone was protected by distal dropping of micro coils or resorbable gelatine. This technique allowed to protect anastomoses while maintaining open prostatic feeding vessels. Embolization of the prostatic artery was performed using the PErFectED technique described by Carnevale et al. [1]: proximal embolization with micro Trisacryl spheres dropped in

medial and lateral branches; second embolization in the distal part of the medial branch when possible.

Arteriographic analysis

Arteriographic images were saved on the intranet of our center. We retrospectively reviewed images of 40 patients, previously anonymised, with two radiologists with more than two years of PAE experience. The objective was to describe precisely, for each patient and each side:

- the origin of the prostatic artery;
- number of prostatic artery(ies);
- the distribution mode of the prostatic artery;
- extra-prostatic anastomosis and the anatomic region concerned.

Data about the necessity of a distal protection (in case of extra-prostatic anastomosis) and the possibility of a second distal dropping (PErFectED) were prospectively collected.

Statistical analysis

Qualitative data were shown with absolute values and proportions. Quantitative data were shown in absolute values and means.

Results

All patients were included in the final analysis. Mean age was 69.5 years (56; 88). Mean prostatic volume was 95.7 mL (40; 210). Prostatic arterial vascularization being bilateral, 80 vascularization modes were analysed.

Origins of the prostatic artery

The different origins of the prostatic artery were summarized in Table 1.

A common arterial trunk for prostate and bladder (anterior trunk) taking its origin from the intern iliac artery was observed in 44 (55%) cases. This anterior trunk distributed one artery for the bladder and one for the prostate. The one for the prostate, going obliquely downwardly towards the medial line, gave on its proximal part the homolateral seminal vesicle artery, and the branches feeding the homolateral hemi-prostate.

In 20 (25%) other cases, the prostatic artery took its origin from the intern pudendal artery. In 14 (17.5%) cases, the prostatic artery took its origin from the obturator artery. It took its origin from the common trunk of the intern iliac artery in one (1.25%) case, and from the superior gluteal artery in one other case (Fig. 1).

Table 1 Origins of the prostatic artery.

Origins of prostatic artery	*n*	%
Anterior trunk	44	55
Obturatory	14	17.5
Internal pudendal	20	25
Internal iliac	1	1.25
Superior gluteal	l	1.25
Total	80	100

Number of prostatic arteries

In 58 (72.5%) cases, prostatic artery was unique. In 21 (26.25%) cases, we observed an accessory prostatic artery. In one case (1.25%), there were two accessory arteries associated to the main one. These accessory arteries took their origin from the intern pudendal artery in 8 (36.4%) cases, the obturator artery in 7 (31.8%) cases, and from the anterior trunk (common trunk distributing the inferior bladder artery and the prostatic one) in 7 (31.8%) cases. However, the accessory artery was always going obliquely downwardly towards the apex, after a distal origin compared to the main one.

Distribution modes

In 30 (37.5%) cases, prostatic artery distributed two branches. We observed the arterial division at the peripheral and basal part of the prostate. A first medial branch went horizontally to the prostatic urethra, along the basal part, under the bladder neck. A second lateral branch went obliquely downwardly towards the apex, along the prostatic capsule, with no anastomotic bound visible with arteriography. This lateral branch gave a third one in 6 cases, going horizontally along the lower part of the medial branch towards the transitional zone of the prostate. In one case, this third artery took its origin from the prostatic artery directly.

We observed extra-prostatic anastomotic bounds in 23 (28.7%) cases. Mostly, the bounds took their origins from the lateral branch of the prostatic artery (18 of the 23 cases, so 78.2%). Rarely, they took their origins from the proximal part of the prostatic artery, before distributing the medial and lateral branches (5 of, so 21.7%). These anastomotic bounds fed two areas: penis via the cavernous artery (39.1%) and rectum via middle rectal artery (60.9%).

In 16 (20%) cases, we observed no division of the prostatic artery, but a unique artery going obliquely downwardly towards the medial line, to the median part of the prostate, and then distributing multiples branches going threw the prostate by a centripetal spreading.

Classification

Our findings can be summarized in five typical cases, depending on the distribution mode of the prostatic artery and presence of extra-prostatic anastomotic bounds:

- type A: division of prostatic artery in two branches, medial and lateral, without any extra-prostatic anastomotic bound (Fig. 2);
- type B: division of prostatic artery in one medial branch and one lateral branch, with a third branch feeding the transitional zone of the prostate. This third artery can take its origin from the lateral branch (B1, represented on Fig. 3), or from the prostatic artery before the division (B2, represented on Fig. 4);
- type C: a unique prostatic artery distributing small multiples centripetal branches (Fig. 5);

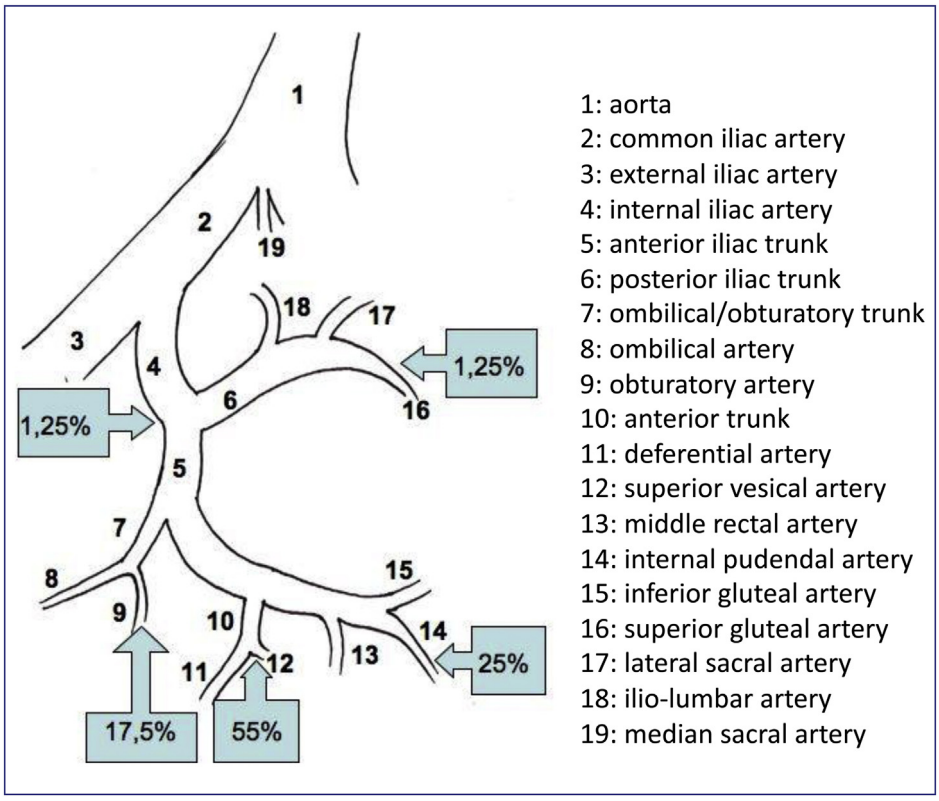

Figure 1. Variability of origins of the prostatic artery. Every situation is pointed by a narrow and the number express the frequency (%).

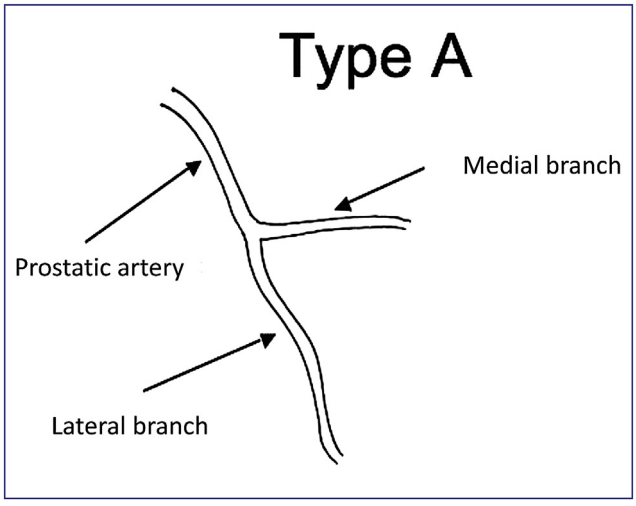

Figure 2. Distribution of type A.

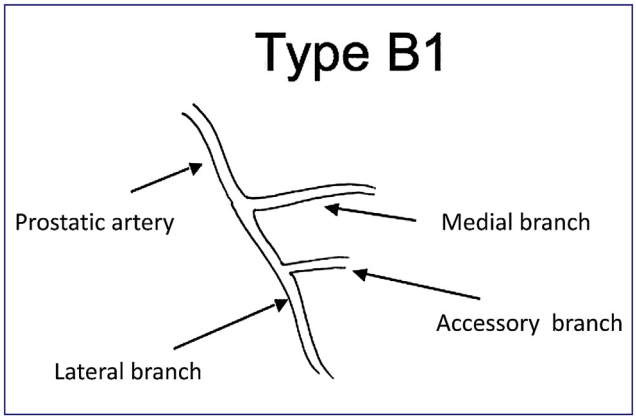

Figure 3. Distribution of type B1.

- type D: extra-prostatic anastomotic bound, homo- or controlateral with a cavernous artery of the penis (Fig. 6);
- type E: extra-prostatic anastomotic bound, homolateral with the middle rectal artery. This bound can take its origin: right from the prostatic artery (E1, represented on Fig. 7) or at the distal part of the lateral branch (E2, represent on Fig. 8).

We could apply this classification for 69 of the 80 cases (86.25%), 11 of them presenting arteriographic reading difficulties. Prevalence of each cases (A, B, C, D, E) are summarized in Table 2. Prevalence of different B types are summarized in Table 3, and E types in Table 4.

Annex 1 present a recapitulative table of the distribution modes observed.

Discussion

Our findings of the origins of the prostatic artery align with common knowledge. In our study, the most frequent situation is the origin of the prostatic artery from a common trunk distributing branches for bladder and prostate (anterior trunk, 55% of the cases). The origin from the pudendal

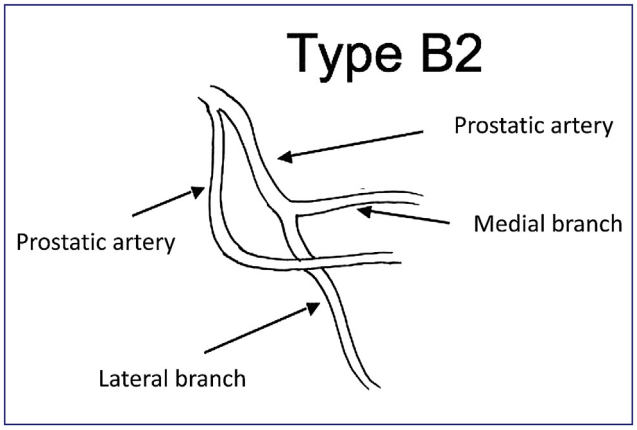

Figure 4. Distribution of type B2.

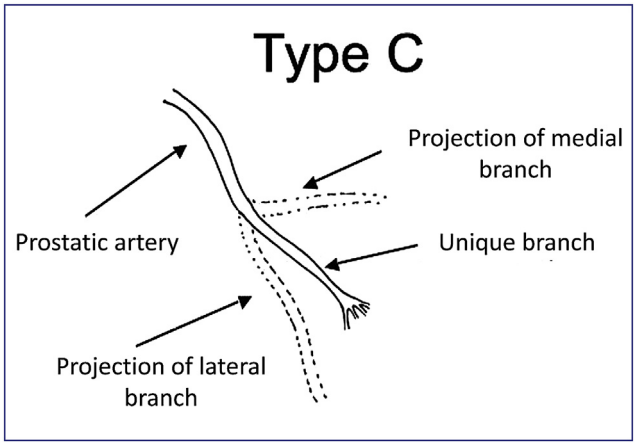

Figure 5. Distribution of type C.

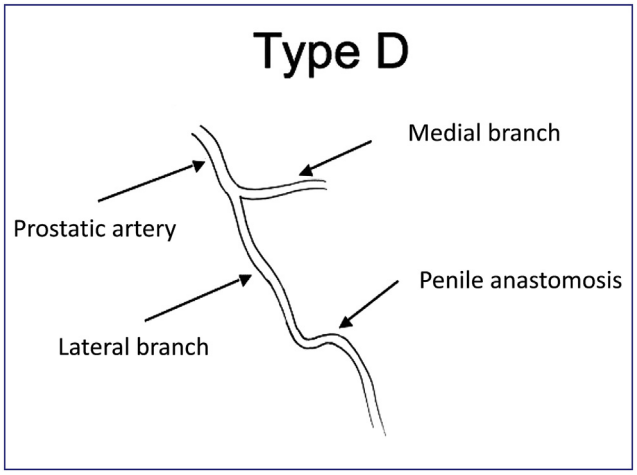

Figure 6. Distribution of type D.

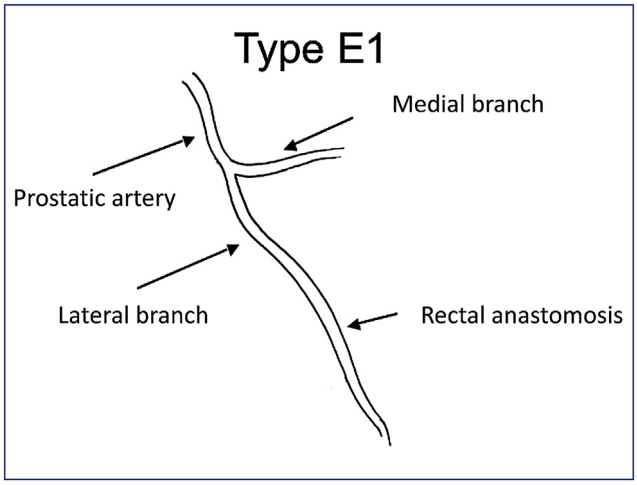

Figure 7. Distribution of type E1.

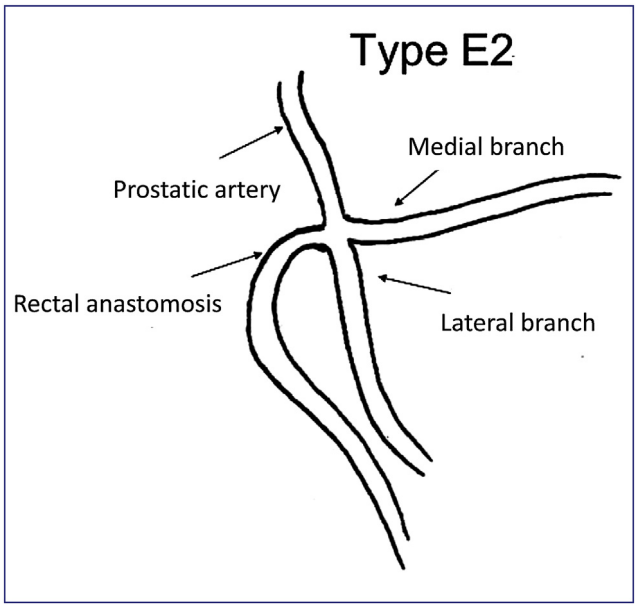

Figure 8. Distribution of type E2.

Table 2 Frequency of cases A, B, C, D and E.

Type	*n*	%
A	23	28.75
B	7	8.75
C	16	20
D	9	11.25
E	14	17.5
Unclassified	11	13.75
Total	80	100

artery or from the obturator artery are the most frequent variations in the literature [7], as in our population.

In 30% of the cases, we observed an accessory prostatic artery feeding the inferior part of the prostate. De Assis et al. [8] find less than 10% of double vascularization in their work. This difference can be explained by a small population sample or by variations of the arteriographic reading. The prevalence of double vascularization should be confirmed in future works, to discuss the benefit of a double embolization.

Before the arteriography era, only one autopsy study described distribution of the prostatic artery [5]. This description fits to our type A, which is the most frequent

Table 3 Frequency of B1 and B2.

B type	*n*	% for *n* = 14	% for *n* = 80
B1	6	86	7.5
B2	1	14	1.25
Total	7	100	8.75

Table 4 Frequency of E1 and E2.

E type	*n*	% for *n* = 14	% for *n* = 80
E1	9	64	11.25
E2	5	36	6.25

situation (28.75% in our population). No variation or anastomotic bounds were described at the time.

Among all the work using arteriography to describe arterial prostatic vascularization [6,8,9], only Amouyal described the distribution of the prostatic artery [6]. Amouyal described 3 subtypes: a presenting a prostatic artery feeding only the prostate, B presenting an anastomotic bound with the rectum, and C with the penis. These results are fitting with ours.

However, we tried to be more specific about the intra-prostatic distribution, and we isolated five different situations. Type A fits the situation described by Garcia-Monaco [5] and then Amouyal [6]. It is the most frequent situation observed in these works, including ours, and seems to be the modal situation. Types A and B are closes, the only difference being the third branch in the B type, feeding the transitional zone in the central part of the prostate. The only difference between sub types B1 and B2 is the origin of this third branch.

D and E types presents an extra-prostatic anastomotic bound, like the two last types described by Amouyal. D type presents an anastomotic bound between the lateral branch and a cavernous artery, while E type present an anastomotic bound with the homolateral middle rectal artery. We observed two subtypes of E, depending on the origin of the bound with the rectal artery: directly from the main prostatic artery (E1) or from the lateral branch (E2).

To the best of our knowledge, C type were never described in the literature. It seems to be a specific anatomical variation, because it does not present a precise division of the prostatic artery, but a main one distributing anarchic small branches at its distal part.

These results provide several perspectives for clinical practice of PAE, first concerning its safety. If an extra-prostatic anastomotic bound is found during the procedure, a protection with resorbable coil or gelatine should be placed. Therefore, type D and E patients should always get the protection procedure. However, we observed that 77.7% of the type D hemi-pelvis of our population did get this protection procedure, and only 35.7% of the type E hemi-pelvis. Our main hypotheses was that the bound was not actually seen during the procedure, but only during the second reading for our study. This could be explained by the experience of the radiologists, superior at the time of the study than the procedure.

Furthermore, concerning the E types, for which we observed only 35.7% of protection, we calculated proportions of sub types that were protected (E1 and E2). In 80% of the cases, sub types E2 were protected, but only 11.1% of E1. This could be explained by the origin of the anastomotic bound: E2 presents an anastomosis at the distal part of the lateral branch, as in type D. The 20% of non-protected E2 types were cases with ''proximal'' selective embolization of the medial branch. In those cases, the radiologist did not embolize the lateral branch on purpose (and so the rectal branch), scarifying some branches going for most of them to the peripheral zone. This decision was taken when the diameters of the distal branches were smaller compared to those from the medial branch. In these situations, we were exposed to the risk of major reflux of the microparticles in the lateral branch during the procedure. No major complications were reported.

However, the 89% of non-protected E1 sub types can be explained by the origin of the anastomosis common trunk of the prostatic artery. Therefore, the distal part of the catheter could be placed in the prostatic artery after the ostium of the rectal branch and before the division, for a proximal embolization.

We used the protection procedure when, even with a catheter position after the ostium of the rectal anastomosis, there was major reflux in the rectal branch. The lack of data about complications (rectorrhagia or erectile disability) for these patients is a limit of our analysis.

Our classification could allow to predict risky situations, and thus anticipate and treat them a reproducible way.

A second perspective is to improve the efficacy of PAE, especially the ''PErFectED'' technique. The ''PErFectED'' technique is more complex but functional results seemed to be better than the standard one [10].

It was described by Carnevale et al. [1], and based on a second embolization at the distal part of medial branch, in addition of proximal embolization of medial and lateral branches. In our study, we observed that 20% of the hemipelvics did not present these lateral and medial branches (type C). We can assume two hypothesis: the PErFectED technique was not realised in these cases, or an another branch was seen as the lateral branch and has been embolized instead. Our classification could improve the standardization of the technique, and thus its reproducibility, which should improve its safety.

Our observations also show for the first time the possibility of a third branch between the medial and the lateral, as described in B type. This branch seems to feed the central part of the prostate, and so the specific region of BPH. This brings the question of selective embolization of this branch, even so it was not described before in the literature. A prospective work analysing the functional results of PAE according to the classification should be able to answer this question.

Several studies appear to be important in the future to investigate our classification, and particularly its predictive skills. First, to associate anatomical subtypes with complications should allow to anticipate risky situations. If the cases with extra-prostatic anastomosis are in fact more likely to give complications as rectorrhagia, erectile disability even necrosis, it would be necessary to establish a standardized prevention procedure, even sometimes

balance the benefits of the intervention. Secondly, to associate the subtypes with functional results should allow to predict efficacy of PAE, and potential failure situations. We should also be able to select patients, and improve the technique for complex cases. Thirdly, an association with prostatic volume and/or intensity of BPH symptoms should allow to predict evolution of BPH for each anatomical subtype. Thus, the classification could be an additional tool to assist the pratician in the technique choice and for decision of an early management.

Our study has limitations, the first one being the lack of data on the efficacy of PAE and complications in our population. To evaluate the evolution of BPH symptoms after PAE should answer the question about the PAE efficacy for type C patients. To analyze the complications should answer the question about security for unprotected D and E patients.

Our study has also internal validity limitations, due to retrospective and single centered characteristics; 13.75% of arteriographies were unclassified, due to reading difficulties. In most cases, the division of the prostatic artery was not visible on the images saved. A prospective work with ''per procedure'' reading should provide better results.

Our observations, and especially the classification, should have external validation by prospective works.

Conclusions

Arterial prostatic anatomy is highly variable. There are multiple origins of the prostatic artery, distribution modes and possibilities of extra-prostatic anastomosis.

The aim of integrating these variations into a classification is to standardize the PAE technique and so improve its security and its feasibility.

These preliminary results should be validated by studies with larger samples, and data about efficacy and complications.

Appendix A. Supplementary data

Supplementary data associated with this article can be found, in the online version, at https://doi.org/10.1016/j.purol.2019.02.007.

Disclosure of interest

The authors have not supplied their declaration of competing interest.

References

[1] Carnevale FC, Antunes AA, da Motta Leal Filho JM, de Oliveira Cerri LM, Baroni RH, Marcelino ASZ, et al. Prostatic artery embolization as a primary treatment for benign prostatic hyperplasia: preliminary results in two patients. Cardiovasc Intervent Radiol 2010;33(2):355—61.

[2] Gao Y, Huang Y, Zhang R, Yang Y, Zhang Q, Hou M, et al. Benign prostatic hyperplasia: prostatic arterial embolization versus transurethral resection of the prostate — a prospective, randomized, and controlled clinical trial. Radiology 2014;270(3):920—8.

[3] Bilhim T, Bagla S, Sapoval M, Carnevale FC, Salem R, Golzarian J. Prostatic arterial embolization versus transurethral resection of the prostate for benign prostatic hyperplasia. Radiology 2015;276(1):310—1.

[4] Clegg EJ. The arterial supply of the human prostate and seminal vesicles. J Anat 1955;89(2):209—16.

[5] Garcia-Monaco R, Garategui L, Kizilevsky N, Peralta O, Rodriguez P, Palacios-Jaraquemada J. Human cadaveric specimen study of the prostatic arterial anatomy: implications for arterial embolization. J Vasc Interv Radiol 2014;25(2):315—22.

[6] Amouyal G, Pellerin O, Del Giudice C, Dean C, Thiounn N, Sapoval M. Variants of patterns of intra- and extra-prostatic arterial distribution of the prostatic artery applied to prostatic artery embolization: proposal of a classification. Cardiovasc Intervent Radiol 2018;41(11):1664—73.

[7] Bilhim T, Pisco JM, Rio Tinto H, Fernandes L, Pinheiro LC, Furtado A, et al. Prostatic arterial supply: anatomic and imaging findings relevant for selective arterial embolization. J Vasc Interv Radiol 2012;23(11):1403—15.

[8] de Assis AM, Moreira AM, de Paula Rodrigues VC, Harward SH, Antunes AA, Srougi M, et al. Pelvic arterial anatomy relevant to prostatic artery embolisation and proposal for angiographic classification. Cardiovasc Intervent Radiol 2015;38(4):855—61.

[9] Zhang G, Wang M, Duan F, Yuan K, Li K, Yan J, et al. Radiological findings of prostatic arterial anatomy for prostatic arterial embolization: preliminary study in 55 chinese patients with benign prostatic hyperplasia. PLoS One 2015;10(7):e0132678.

[10] Carnevale FC, Iscaife A, Yoshinaga EM, Moreira AM, Antunes AA, Srougi M. Transurethral resection of the prostate (TURP) versus original and perfected prostate artery embolization (PAE) due to benign prostatic hyperplasia (BPH): preliminary results of a single center, prospective, urodynamic-controlled analysis. Cardiovasc Intervent Radiol 2016;39(1):44—52.